

# Rectal Prolapse in Infants and Children

Diller B. Groff, MD, Hirikati S. Nagaraj, MD, Louisville, Kentucky

**Rectal prolapse that is intractable to the usual medical therapy was successfully managed without significant complications in 10 patients by simple subcutaneous encirclement of the anus with a heavy nonabsorbable suture, which was in place until the suture was removed or broke after 4 to 6 months. Four patients required two sutures and one needed a third insertion. Since this procedure is simple, has no serious complications, and controls rectal prolapse, it is recommended as the preferred initial surgical treatment of this condition.**

**R**ectal prolapse is a condition that is often seen in infancy and is usually managed by the pediatrician or family practitioner. Prevention of constipation, expeditious reduction of the prolapse by the parents, and normal growth and development are the keys to successful nonsurgical management [1,2].

Nevertheless, there are some otherwise healthy children who do not respond to this regimen, and there are some "problem" children whose parents are too upset by the prolapse to care for it properly or become discouraged over the length of time necessary before treatment is successful. We have found that a modified Thiersch perianal suture technique is an effective, simple, and safe method of treatment for rectal prolapse and present our experience to encourage use of this established, but often overlooked, therapy.

## ETIOLOGY

Patients with myelomeningocele, exstrophy of the bladder, cystic fibrosis, or chronic lung disease more frequently develop rectal prolapse [1,2]. In the otherwise healthy child, the absence of the sacral curve, which causes the rectum to be more vertical, poorly developed valves of Houston, and immature lateral ligaments of the rectum all contribute to an increased susceptibility to rectal prolapse. Constipation and diarrhea are often associated with the initial prolapse.

From the Department of Surgery, Division of Pediatric Surgery, University of Louisville School of Medicine, and Kosair Children's Hospital, Louisville, Kentucky.

Requests for reprints should be addressed to Diller B. Groff, MD, Pediatric Surgery, Kosair Children's Hospital, P.O. Box 35070, Louisville, Kentucky 40232-5070.

Manuscript submitted June 13, 1989, and accepted in revised form January 24, 1990.

## DIAGNOSIS

Initial presentation of the prolapse is a red ring of mucosa from the rectum after defecation. This is also associated with mucus, bloodstained clothing, or blood in the stools. Neglected prolapsed bowel becomes edematous, gets excoriated, and bleeds more frequently. In mild cases, the prolapse will often reduce itself after defecation.

The differential diagnosis of rectal prolapse must include ileocecal intussusception protruding through the anus. Although the child with intussusception is usually sick, while the child with prolapse is well, the examiner can distinguish these two conditions by passing his or her finger between the prolapsed bowel and the anal sphincter. This is possible with intussusception, but in rectal prolapse the protruding mucosa is continuous with the perianal skin, and the finger will not pass this junction.

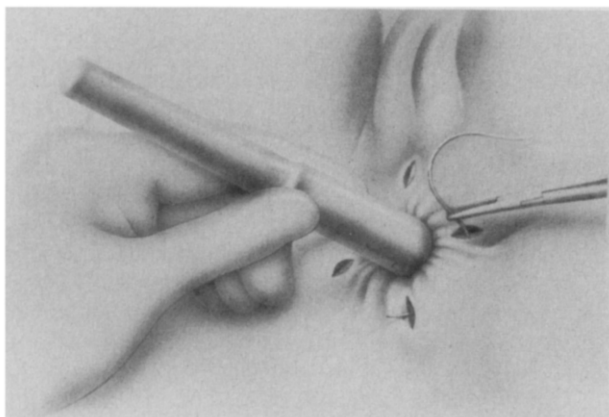
## TREATMENT

Ten patients (6 boys, 4 girls) have been treated over a 4-year period after the usual conservative treatment methods had failed. The prolapse was mucosal, involving most of the anus in nine patients, and was a complete prolapse (procidentia) in the patient with a meningocele. Six patients were otherwise healthy. One had a myelomeningocele and three had multiple congenital anomalies associated with bronchopulmonary dysplasia. The otherwise healthy children were all over 2 years of age.

Surgery was performed under masked general anesthesia with local anesthesia at the perianal incision sites. No enemas or bowel preparations were used; however, preoperative enemas or rectal irrigation under anesthesia may be occasionally needed. The prolapsed bowel was reduced and two or four quadrant incisions were made at the mucocutaneous junction through the skin to the subcutaneous tissue. These small incisions ensure that the suture and the knot are deep in the subcutaneous tissue. A 0 or no. 1 nonabsorbable prolene suture on a swaged needle was then passed subcutaneously around the anus outside of the external sphincter (Figure 1). The suture was tightened to an appropriate size for age—a Hegar dilator, size 7 or 8 for the smaller infants, to size 13 for the 5-year-old patient. We have even tightened the anus down to a size 5 or 6 in two patients and had no problems with constipation. The skin incisions were closed with a fine absorbable suture. Some patients were given stool softeners postoperatively, but this was not done routinely.

## RESULTS

There were no wound infections or serious complications. Constipation was not a problem. Sutures remained in place an average of 7 months (range: 1.5 to 24) and were left in place in three patients. Sutures broke in three of five patients with an absorbable polydioxanone suture, but in only two of nine patients with the heavy prolene



**Figure 1.** The principal techniques of the modified Thiersch suture are illustrated. A proper-sized Hegar dilator is used to keep the anus from being too constricted.

sutures. Four patients had two sutures placed, and one required a third suture. All patients had the prolapse controlled by the suture and were cured when the suture was removed or broke after 4 to 6 months (mean: 3 months). There were no problems with skin breakdown, although the knot worked itself to the surface in three patients. One infant died of pulmonary complications not related to the procedure.

#### COMMENTS

Oeconomopoulos and Swenson [1] in 1960 reported excellent results with the Thiersch suture in nine children. However, six of their children had exstrophy of the bladder, one had myelomeningocele, and one had cystic fibrosis; only one was otherwise healthy. Their experience was similar to ours except that more than half of our patients were otherwise healthy children. Oeconomopoulos and Swenson [1] also found that a heavy nonabsorbable suture was necessary to minimize problems with breakage.

As in our series, there were no problems with perineal infections, drainage, or extrusion of the sutures. Our children were asymptomatic with the suture in place and no child developed constipation.

The most current literature reports the results of major abdominal surgery for childhood rectal prolapse [3-5], extensive mucosa stripping [5], or the retrorectal injection of sclerosing materials [6]. All of these operations are reported to have cured the rectal prolapse. In fact, Corman [2] reported in his review article that the treatment success rate is virtually 100% for all reported procedures. The modified Thiersch procedure described does not require laparotomy, does not involve blind injection of potentially toxic sclerosing materials, or risk perforation of the rectum with mucosal stripping techniques. In addition, if the suture breaks, it is easily inserted again. Since the rate of success for the modified Thiersch procedure using prolene is so high, and complications so low, we strongly recommend starting with this procedure as described. Since the procedure is so safe, we also encourage primary care physicians to refer children with problem rectal prolapse not responding to nonsurgical measures for earlier surgical treatment.

#### REFERENCES

1. Oeconomopoulos CT, Swenson O. Thiersch's operations for rectal prolapse in infants and children. *Am J Surg* 1960; 100: 457-61.
2. Corman ML. Rectal prolapse in children. *Dis Colon Rectum* 1985; 28: 535-9.
3. Qvist N, Rasmussen L, Klaaborg KE, *et al.* Rectal prolapse in infancy: conservative versus operative treatment. *J Pediatr Surg* 1986; 21: 887-8.
4. Chino ES, Thomas CG. Transsacral approach to repair of rectal prolapse in children. *Am Surg* 1984; 50: 70-5.
5. Momoh JT. Quadrant mucosal stripping and muscle plecting in the management of childhood rectal prolapse. *J Pediatr Surg* 1986; 21: 36-8.
6. Leape LL. Other disorders of the rectum and anus. In: Welch KJ, ed. *Pediatric surgery 2*. Chicago: Year Book Medical Publishers, 1986: 1042-3.