

PediatricsinReview®

Screening for Genitourinary Abnormalities in Adolescent Males

Robert M. Cavanaugh, Jr
Pediatrics in Review 2009;30;431
DOI: 10.1542/pir.30-11-431

The online version of this article, along with updated information and services, is located on the World Wide Web at:
<http://pedsinreview.aappublications.org/content/30/11/431>

Pediatrics in Review is the official journal of the American Academy of Pediatrics. A monthly publication, it has been published continuously since 1979. Pediatrics in Review is owned, published, and trademarked by the American Academy of Pediatrics, 141 Northwest Point Boulevard, Elk Grove Village, Illinois, 60007. Copyright © 2009 by the American Academy of Pediatrics. All rights reserved. Print ISSN: 0191-9601.

American Academy of Pediatrics

DEDICATED TO THE HEALTH OF ALL CHILDREN™



Screening for Genitourinary Abnormalities in Adolescent Males

Robert M. Cavanaugh, Jr,
MD*

Author Disclosure
Dr Cavanaugh has disclosed no financial relationships relevant to this article. This commentary does not contain a discussion of an unapproved/investigative use of a commercial product/device.

Objectives After completing this article, readers should be able to:

1. Describe the importance of screening for genitourinary problems in adolescent boys.
2. Delineate the essential components of screening urology in adolescent boys.
3. Explain when and how to perform sexually transmitted infection testing in adolescent boys.
4. Counsel adolescent boys on sexuality-related issues.

Introduction

Pediatricians and other pediatric clinicians are in an ideal position to screen for genitourinary problems in adolescent boys. Much information can be gathered by screening for sexuality-related issues and by investigating specific genitourinary symptoms as they occur. Routine inspection of the genitalia should be considered an essential component of the regular examination for adolescent boys. This article reviews important *asymptomatic* genitourinary conditions in young men that can be detected in the pediatric office.

Taking the History

The routine history for adolescent boys should address reproductive health-care issues, including questions about the dramatic physical changes, intense emotional feelings, and sexual experiences that occur during puberty as well as any specific genitourinary complaints. These and other sensitive issues should be discussed privately with the clinician, unless the patient specifically requests otherwise. Most parents understand the importance of their adolescent having time alone with the examiner and respect his need for privacy. In certain circumstances and in accordance with state laws (see Guttmacher Institute, www.guttmacher.org), confidentiality and treatment of minors younger than 18 years of age may be permitted without parental or legal guardian consent, although open communication always should be encouraged. For an in-depth discussion on confidential health care for adolescents, the reader is referred to the position paper published by The Society for Adolescent Medicine cited in the Suggested Reading list.

Clinicians can screen quickly for reproductive health care issues in adolescent boys by asking “trigger” questions (Table 1). General questions regarding pubertal changes are a useful lead into a more detailed sexual history. To initiate this discussion, patients can be asked, “Do you think you are growing normally?” They then can be asked, “Do you have any questions or concerns about your looks or appearance?” and “Do you have any questions or concerns about your sexual development?” It is important to follow up on any positive responses. One useful technique is using open-ended questions, such as, “Can you tell me about this?” The patient is asked progressively more detailed questions in an effort to determine if any further evaluation or treatment is warranted (Cavanaugh 2007).

A discussion on sexual desires can be initiated by asking the patient, “Are you in a romantic relationship with anyone?” If the patient answers yes, the follow-up question can be, “Tell me about your partner(s).” Avoid heterosexually biased words such as “girl-friend” and do not assume that all boys have a heterosexual orientation. When speaking with 10- to 14-year-old adolescents, it is important to remember that same-sex experimentation is very common in this age group and often precedes self-identification of sex.

Asking male patients, “Do you feel different from other boys?” may uncover concerns about sexual identity. If they have concerns, it is important to determine what makes them feel that way. This inquiry usually reflects acknowledgment of their individuality. How-

*Professor of Pediatrics, Director of Adolescent Medicine, SUNY Upstate Medical University, Syracuse, NY.

Table 1. Trigger Questions for Sexual Changes, Feelings, and Experiences

Stage of Development

1. "Do you think you are growing normally?"
2. "Do you have any questions or concerns about your looks or appearance?"
3. "Do you have any questions or concerns about your sexual development?"

Sexual Desires

4. "Are you in a romantic relationship with anyone?" If yes, "Tell me about your partner."
5. "Do you feel different from other boys?"
6. "Are you interested in girls?"
7. "Are you more attracted to boys than to girls?"
8. "Are you familiar with the terms masturbation, ejaculation, and wet dreams?" If yes, "Do you believe any of these are abnormal or harmful?"

Sexual Experiences

9. "Are any of your friends sexually experienced?" "How about you?" OR "Have you ever had any sexual experiences?"
10. "Are you *thinking* about being sexually active with anyone sometime soon?"
11. "Have you ever felt forced or pressured into having sex with anyone?"

Modified and reproduced with permission from Cavanaugh RM. Screening adolescent gynecology in the pediatrician's office: have a listen, take a look. *Pediatr Rev.* 2007;28:332-342.

ever, feeling different from others of the same sex can be a subtle clue to a young person's sexual orientation. Boys who feel different from other boys, are not interested in girls, and are more attracted to boys than to girls can be asked, "Do you feel you may be gay or bisexual?" The responses to questions about sexual identity have important implications for further sexuality counseling. The articles by Catalozzi and Mravcak offer additional information on taking sexual histories from youth who may be gay or bisexual.

Masturbation and nocturnal emissions are additional important issues to address. Boys can be asked, "Are you familiar with the terms masturbation, ejaculation, and wet dreams?" Those who answer yes can be asked, "Do you believe any of these are abnormal or harmful?" Patients who feel that any of these behaviors are abnormal or harmful should be educated that they are normal, healthy forms of sexual expression that are very common in young men as well as their adult male counterparts.

The subject of sexual experiences can be raised by asking, "Are any of your friends sexually experienced?" and then "How about you?" Another technique is to ask the patient directly "Have you *ever* had any sexual experiences?" If the patient has had sexual experiences, the clinician can ask, "What type of experiences have you had?" The reply may be hugging, kissing, petting, or similar activities that do not require any further evaluation. However, it is also important to ask specifically about oral, anal, and genital sex, so samples for sexually transmitted infection (STI) testing can be obtained from the appropriate mucosal surfaces. One way of asking the question is by stating, "There are different kinds of sex: oral, anal, and genital. What kinds of sex are you having?" Most adolescents are familiar with these words, but in some cases the examiner may need to explain the terms in developmentally appropriate ways to obtain accurate answers. Another approach to follow-up for patients who give a positive history for sexual experiences is to ask, "Have your experiences been with boys, girls, or both?" This question is not threatening to adolescents as long as the clinician explains that the same question is routinely asked of *all* of patients who have had sexual experiences.

Young men who are thinking about becoming sexually active should be offered information on contraception and STI prevention. Patients who may be engaging in heterosexual or bisexual relationships may need information on contraception; those who may be engaging in homosexual relationships may not. Boys who have been sexually abused or who have felt forced or pressured into having sex with someone are at considerable risk for ongoing distress or injury. Every effort must be made to identify these individuals as soon as possible, so appropriate intervention can be initiated to minimize adverse sequelae. A good trigger question is, "Have you *ever* felt forced or pressured into having sex with anyone?"

Although this article focuses on *asymptomatic* conditions, clinicians should screen routinely for genitourinary problems in adolescent boys as part of the review of systems, including asking about pain in the lower abdomen as well as pain, swelling, or discomfort in the inguinal region, scrotum, and testes. More specific urinary symptoms include urgency, frequency, pain with urination, difficulty initiating stream, dribbling, incomplete bladder emptying, penile discharge, and incontinence or enuresis. Concern about genital size and worries about sexual function are also relatively common in young men.

Performing the Physical Examination

The external genitalia should be assessed as part of a routine examination in adolescent boys because a num-

Table 2. Findings Missed in Asymptomatic* Adolescent Boys If External Genitalia Not Examined

Ambiguous Genitalia

Sexual Maturity Rating

Penile Abnormalities

Ventral penile bending or chordee
Hypospadias
Epispadias
Phimosis or paraphimosis
Meatal stenosis
Buried or concealed penis

Cord Structures

Hernia
Hydrocele (rarely due to cancer)
Varicocele
Mass lesion, such as fibroma

Testicular Abnormalities

Undescended testicle(s)
Horizontal lie (may be associated with increased risk for torsion)
Macroorchidism: eg, fragile X syndrome
Hypoplasia: eg, Klinefelter syndrome
Mass lesion
Malignancy
Spermatocoele

Dermatologic Conditions

Dysplastic nevi, malignant melanoma
Condyloma accuminata, condyloma lata
Chancre of primary syphilis

Sexual Abuse or Self-mutilation

Lacerations, burns, hemorrhagic lesions, scarring, other signs of trauma

Genital Piercings

Soft-tissue Sarcomas

Paratesticular rhabdomyosarcoma and others

Perianal Findings

Fistulae, fissures, tags, and others

Instruction on testicular self-examination, especially in older adolescents

*Includes patients who are unable or unwilling to report symptoms.

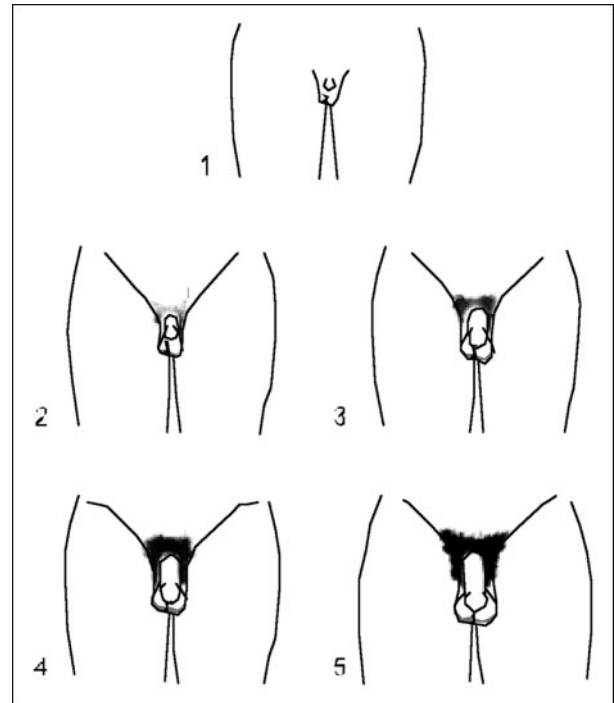


Figure 1. Sexual Maturity Rating for male genitalia. Reprinted with permission from Rosen DS. Physiologic growth and development during adolescence. *Pediatr Rev.* 2004;25:194–200.

ber of *asymptomatic* conditions may be detected (Table 2). It must be stressed that young men often are too shy or embarrassed to volunteer information that may alert the clinician to genital abnormalities. They also may be completely unaware that they have a congenital or acquired abnormality, especially if their genitalia have not been examined during health supervision visits. In addition, adolescent boys frequently are very self-conscious about genital size, and it is important to reassure them when everything is normal. This practice is especially true for the obese boy whose penis is normal in size but appears small because it is buried or partially concealed by adipose tissue.

A thorough knowledge of the principles of pubertal development greatly enhances the clinician's ability to care for young men. It is essential to document maturation of the genitalia and development of pubic hair at regular intervals. Use of the Sexual Maturity Rating (SMR) has simplified this process (Figs. 1 and 2 and Table 3). The findings should be interpreted in context with other growth data, including height, weight, and body mass index, with percentiles plotted for each. Deviation from expected parameters for any of these mark-

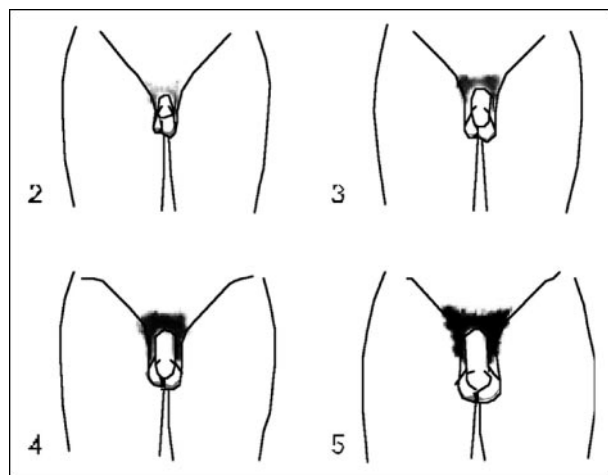


Figure 2. Sexual Maturity Rating for pubic hair. Reprinted with permission from Rosen DS. Physiologic growth and development during adolescence. *Pediatr Rev.* 2004;25:194–200.

ers may be the initial manifestation of a significant underlying problem.

A number of significant skin lesions affecting the external genitalia may be completely asymptomatic in adolescent boys. The foreskin should be retracted, if necessary, to exclude underlying dermatologic conditions as well as any penile or urethral abnormalities (Table 2). Genital warts (condyloma acuminata) caused by human papillomavirus (HPV) are very common in young men and are spread primarily through sexual contact. Infection with HPV can lead to considerable morbidity, especially when transmitted to young women. Although most genital ulcers are painful, some may be totally asymptomatic, as is characteristic of the chancre of primary syphilis. It also is important to consider syphilis testing when verrucous lesions are seen in the anogenital area because the wartlike papules of condyloma lata that occur in secondary syphilis closely resemble the warts of condyloma acuminata.

Malignant melanomas of the genital area are rare in adolescents, but they do occur. This serious form of skin cancer may form de

novo or develop from predisposing lesions such as congenital pigmented nevi or dysplastic nevi. Routine inspection of the genitalia by the clinician is especially important for patients who have dysplastic nevi in other parts of the body or who have a family history of dysplastic nevi or melanoma. Adolescent boys may be totally unaware that a lesion is present, especially if it is located on the underside of the scrotum or other relatively hidden area. If they do notice an area of concern, they may not bring it to medical attention in a timely manner.

Simple inspection of the genitalia also may reveal lacerations, burns, scarring, or other evidence of trauma. Such lesions may be unreported by adolescent boys, especially in cases of sexual abuse or self-mutilation. Hemorrhagic lesions in the genital area always should raise suspicion for the latter two diagnoses, especially if the lesions are not pruritic, which is more typical of dermatologic conditions. In addition, young men who have genital piercings can develop infections, bleeding, and allergic reactions following the initial procedure or even when the jewelry is changed. Such boys should be counseled to seek prompt medical attention at the earliest sign of complications to prevent spread of infection and to minimize scarring and disfigurement.

Normal scrotal anatomy is shown in Figure 3. The scrotal examination includes palpation of the cord struc-

Table 3. Sexual Maturity Rating (Tanner) Genital and Pubic Hair Stages and Ages of Sexual Development in Males

Stage	Age (years)
Genitalia	
1. Prepubertal testis <2 cm	
2. Testis >2.5 cm, >4 mL	11.8 (9.8 to 14.2)
3. Testis >3 cm, >6 mL; phallus has grown in length	13.0 (11.7 to 14.6)
4. Peak height velocity	13.8 (11.5 to 16.0)
Testis >4 cm, >10 mL; phallus has grown in breadth	14.3 (12.6 to 15.8)
5. Adult testis >5 cm, >15 mL	15.1 (12.9 to 17.0)
Pubic Hair	
1. None	
2. Slightly pigmented at base of phallus or on scrotum	12.2 (10.7 to 13.8)
3. Dark, coarse at base of phallus	13.9 (12.0 to 15.7)
4. Adult in character; confined to suprapubic region	14.8 (12.9 to 16.4)
5. Adult—spread to medial thigh	15.3 (13.8 to 16.8)

Data from Lee PA. Disorders of puberty. In: Lifshitz F, ed. *Pediatric Endocrinology*. 3rd ed. New York, NY: Marcel Dekker Inc; 1996:175–95. Reprinted with permission from Root AW. Precocious puberty. *Pediatr Rev.* 2000;21:10–19.

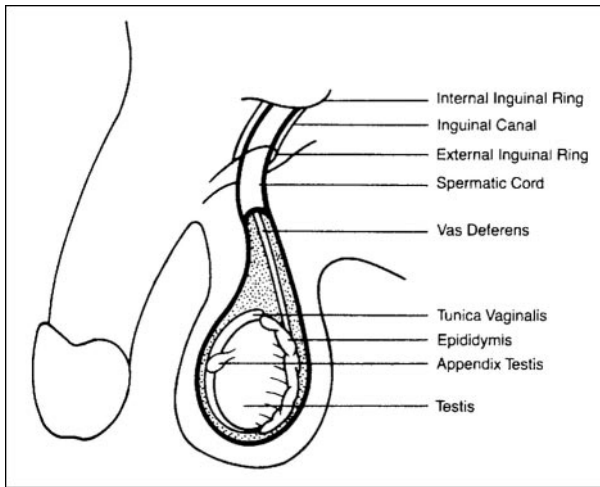


Figure 3. Normal scrotal anatomy. Reprinted with permission from Kappahn C, Schlossberger N. Male reproductive health: part 1. Painful scrotal masses. *Adolesc Health Update*. 1992; 4(3):1–5, 8.

tures for potential problems noted in Table 2. It is important to examine the male genitalia when the patient is in the upright position to diagnose a hernia, detect a varicocele, or recognize a testicle that has a horizontal lie and may be associated with a predisposition to torsion. Any of these conditions may be asymptomatic but can be associated with significant complications. Their presence may not be apparent, unless the patient is examined while he is standing.

A varicocele is caused by dilation of the pampiniform plexus of veins and feels like a “bag of worms” on palpation. This relatively common finding usually occurs in the upper left area of the scrotum, largely because of the differences in the venous drainage patterns of the right and left testicular veins. The left testicular vein drains into the left renal vein and the right testicular vein drains directly into the vena cava. Most patients are asymptomatic, but detection is important because a varicocele may be associated with decreased testicular volume on the affected side, decreased spermatogenesis, and decreased sperm motility. A varicocele normally presents after puberty but before age 25 years, usually occurs on the left side, and disappears when the patient lies down. A mass lesion should be suspected if the varicocele presents prepubertally or after age 25 years, persists in the supine position, or is present on the right side. In addition, a varicocele on the right side may be associated with situs inversus or simply may be a normal variant.

The long axis of the testes usually is vertical when the

patient is examined in the standing position. A congenital high attachment of the tunica vaginalis on the posterior wall of the scrotum allows the testis to rotate on the cord, within the tunica vaginalis. This is the “bell-clapper” deformity, manifesting as a horizontal lie of the testicle instead of the normal vertical lie. Such a testicle is prone to torsion because it has lost its normal attachment to the posterior wall of the scrotum and it may hang freely, like the clapper in a bell (Eaton 2005). The “bell-clapper” deformity commonly is bilateral, which places the contralateral testicle at risk for torsion. A boy who has a horizontal-lying testicle should be referred to a urologist or similarly qualified individual who has expertise in male genital abnormalities. Referral is especially necessary if the patient has a history of unexplained testicular pain, which could represent torsion with spontaneous resolution.

The testes also should be assessed for size, symmetry, descent, and masses. Normal testicular size is noted in Table 3. Although testicular cancer is a leading cause of malignancy in young adult males, teaching self-examination of the scrotum to adolescent boys is somewhat controversial at this time. Currently, there is no evidence that this examination increases the early detection of testicular cancer in this population, but performing the examination does raise awareness to changes. At our adolescent medicine center, we believe that the choice of whether to perform a monthly self-examination is one that a young man should make for himself. Instruction is offered to patients who appear to be mature enough to understand this information and whose genital development has progressed to SMR 4 or 5. It is especially important that monthly examinations be considered seriously in patients who have certain risk factors (Adelman and Joffe 2005) that increase their chance of developing testicular cancer, such as cryptorchidism or a family history of the disease. Evaluation of a testicular mass should begin with ultrasonography. As noted in the article by Adelman and Joffe, an in-depth evaluation subsequently can be performed as indicated.

An external anal inspection should be performed in adolescent boys to look for several important disorders. Any of the findings associated with the skin conditions described previously may involve the perianal region, including the dermatologic changes associated with sexual abuse. Many perianal lesions, including fissures, fistulae, or tags, are asymptomatic and may precede development of more serious complications of underlying conditions, such as inflammatory bowel disease.

Laboratory Investigation

STIs are epidemic among teenagers and may be associated with significant complications, including an increased risk for the acquisition and transmission of the human immunodeficiency virus (HIV). Most males who have STIs are asymptomatic. *Asymptomatic* male adolescents also serve as an important silent reservoir for transmission of STIs to young women, who may develop serious complications such as pelvic inflammatory disease, ectopic pregnancy, cervical cancer, and infertility. Currently, there are no uniform guidelines for screening for *Chlamydia trachomatis* and *Neisseria gonorrhoeae* infections in sexually active young men who are asymptomatic. At our center, boys who have a history of oral, genital, or anal sex are screened routinely for *Chlamydia* infection and gonorrhea, as outlined in Table 4. The importance of undergoing serologic testing for HIV and syphilis is stressed to these patients.

Ascertaining specific sexual practices allows determination of appropriate sites and methods for screening asymptomatic young men for *Chlamydia* infection and gonorrhea. The pros and cons of available methods are discussed by Burstein and Murray (2003). At our center, we use the urine leukocyte esterase test, a rapid, inexpensive dipstick assay to determine which asymptomatic boys who have a history of genital sex need to be tested for *Chlamydia* infection and gonorrhea using more costly methods, such as nucleic acid amplification testing (NAAT). Detection of pharyngeal or rectal gonorrhea and rectal *Chlamydia* infection still requires culture. Pharyngeal infection with *C trachomatis* is uncommon, and routine screening for it is not recommended. Because of their high degree of specificity, cultures for gonorrhea and *Chlamydia* are recommended in medicolegal cases, such as when sexual abuse is suspected.

False-positive results may occur with NAAT testing,

especially in low-prevalence populations. Although this may be problematic in certain clinical situations, it is recommended that all positive screening tests be considered presumptive evidence of infection. Patients reported to have a positive result should receive prompt treatment and be counseled to notify any sexual partners, so they also can receive appropriate evaluation and treatment, as indicated. An additional test should be considered if a false-positive screening test would result in substantial adverse medical, social, or psychological impact on the patient.

Management

Once the screening history and physical examination have been performed, adolescent boys can be counseled on reproductive health care needs and any genitourinary complaints. Depending on the clinician's knowledge, experience, and comfort level, counseling can be performed in the office or the patient can be referred to a practitioner who may be better equipped to carry out this essential role.

Sexuality counseling should be individualized according to specific sexual feelings and practices. Those adolescents who are having a difficult time dealing with sexual identity issues should be given support and guidance. Boys who feel they are gay or bisexual should be counseled in accordance with their individual needs (Catalozzi 2004, Mravcak 2006).

Sexually active males should be screened for STIs. Continued abstinence always should be supported for adolescents who are abstinent. Information on postponing sexual involvement, contraception, and prevention of STIs should be provided as needed. This information should include the consistent and correct use of condoms with every act of intercourse. In addition, young men who may be engaging in heterosexual or bisexual relationships should be offered information on contraception, including the availability of emergency contraception, and indications for its use (Conrad 2006).

Syphilis, gonorrhea, *Chlamydia* infection, chancroid, HIV infection, and acquired immune deficiency syndrome are reportable diseases in every state. The requirements for reporting other STIs differ by state, and clinicians should be familiar with state and local reporting requirements. Reporting can be clinician- or laboratory-based. Clinicians who are unsure of state and local reporting requirements should seek advice from state or local health departments or STI programs (Centers for Disease Control and Prevention 2006).

Table 4. Screening for Gonorrhea and *Chlamydia* in Asymptomatic Young Men*

1. Pharyngeal: Gonorrhea culture only
2. Urine: Leukocyte esterase test or nucleic acid amplification testing (NAAT) for gonorrhea and *Chlamydia*
3. Urethral: Culture or NAAT for gonorrhea and *Chlamydia* infection
4. Rectal: Gonorrhea and *Chlamydia* culture only

*As determined by specific sexual practices.

Summary

- Screening for genitourinary problems is an essential component of routine preventive health care for adolescent boys.
- A number of significant asymptomatic conditions can be easily missed unless an adequate evaluation is performed
- Much information can be gathered by taking the history, examining the genitalia, and ordering simple screening studies as indicated. The pediatric office is the ideal setting in which to perform these basic services, with referrals for a more complete evaluation or in-depth counseling as needed.
- Failure to meet the reproductive health-care needs of young men during their regular health maintenance visits represents an important missed opportunity.

Suggested Reading

- Adelman WP, Joffe A. Consultation with the specialist: testicular masses/cancer. *Pediatr Rev.* 2005;26:341–344
- Burstein GR, Murray PJ. Diagnosis and management of sexually transmitted disease pathogens among adolescents. *Pediatr Rev.* 2003;24:75–82
- Catalozzi M, Rudy BJ. Lesbian, gay, bisexual, transgendered, and questioning youth: the importance of a sensitive and confidential sexual history in identifying the risk and implementing treatment for sexually transmitted infections. *Adolesc Med Clin.* 2004;15:353–367
- Cavanaugh RM. Managing the transitions of early adolescence. *Adolescent Health Update.* 2008;20(3):1–9
- Cavanaugh RM. Screening adolescent gynecology in the pediatrician's office: have a listen, take a look. *Pediatr Rev.* 2007;28:332–342
- Centers for Disease Control and Prevention. Sexually transmitted diseases guidelines, 2006. *MMWR Morbid Mortal Wkly Rep.* 2006;55(No. RR-11)
- Conrad LAE, Gold MA. What you need to know about providing emergency contraception. *Contemp Pediatr.* 2006;23(2):49–70
- Eaton SH, Cendron MA, Estrada CR, et al. Intermittent testicular torsion: diagnostic features and management outcomes. *J Urol.* 2005;174:1532–1535
- Gruenwald Pfeifer K, Middleman AB. *American Medical Association Boy's Guide to Becoming a Teen.* Chicago Ill: American Medical Association; 2006
- Guttmacher Institute. State policies in brief: an overview of minors' consent law (as of October 1, 2008). Available at: www.guttmacher.org. Accessed August 2009
- Hagan JF, Shaw JS, Duncan PM, eds. *Bright Futures: Guidelines for Health Supervision of Infants, Children, and Adolescents.* 3rd ed. Elk Grove Village, Ill: American Academy of Pediatrics; 2008
- Holland-Hall C. Sexually transmitted infections: screening, syndromes, and symptoms. *Prim Care.* 2006;33:433–454
- Mravcak SA. Primary care for lesbians and bisexual women. *Am Fam Physician.* 2006;74:279–286
- Society for Adolescent Medicine. Confidential health care for adolescents: position paper of the Society for Adolescent Medicine. *J Adolesc Health* 2004;35:160–167

PIR Quiz

Quiz also available online at pedsinreview.aappublications.org.

21. A 16-year-old boy comes to your office for an initial health supervision visit with you. You strive to make him understand that you are truly interested in him by discussing his assets, ambitions, hobbies, home life, school performance, and experience with recreational drugs. Of the following, the *most* appropriate approach to establish his sexual orientation is to ask:
 - A. "Are you aware of the different kinds of sex?"
 - B. "Are you in a romantic relationship?"
 - C. "Do you have a girlfriend?"
 - D. "Have you ever performed anal intercourse?"
 - E. "Have you ever wanted to hug another boy?"

22. Following successful completion of the history and general examination for the 16-year-old patient, you examine his genitalia. Of the following, you should be *most* concerned about finding:
 - A. A left-sided varicocele that disappears in the supine position.
 - B. SMR 3 pubic hair.
 - C. SMR 4 pubic hair.
 - D. The long axes of the right and left testes to be 4.5 cm and 5 cm, respectively.
 - E. The long axis of the left testicle to be horizontal.

23. Most males who have sexually transmitted infections are asymptomatic. If sexual abuse is not suspected, in high-prevalence settings, nucleic acid amplification testing is a reliable, albeit expensive, method to screen for:
 - A. Penile *Treponema pallidum*.
 - B. Pharyngeal *Chlamydia trachomatis*.
 - C. Pharyngeal *Neisseria gonorrhoeae*.
 - D. Rectal *Chlamydia trachomatis*.
 - E. Urethral *Neisseria gonorrhoeae*.

24. The otherwise healthy 16-year-old adolescent male who is in *greatest* need of counseling is one who:
 - A. Admits to having been pressured into having sex.
 - B. Has not yet dated.
 - C. Is worried about the size of his penis.
 - D. Masturbates regularly.
 - E. Uses condoms for most intercourse.

Screening for Genitourinary Abnormalities in Adolescent Males

Robert M. Cavanaugh, Jr
Pediatrics in Review 2009;30;431
DOI: 10.1542/pir.30-11-431

Updated Information & Services

including high resolution figures, can be found at:
<http://pedsinreview.aappublications.org/content/30/11/431>

References

This article cites 10 articles, 3 of which you can access for free at:
<http://pedsinreview.aappublications.org/content/30/11/431#BIBL>

Subspecialty Collections

This article, along with others on similar topics, appears in the following collection(s):
Adolescent Medicine/Gynecology
http://pedsinreview.aappublications.org/cgi/collection/adolescent_medicine_gynecology
Genital System Disorders
http://pedsinreview.aappublications.org/cgi/collection/genital_system_disorders
Gynecology
http://pedsinreview.aappublications.org/cgi/collection/gynecology_sub
Urology
http://pedsinreview.aappublications.org/cgi/collection/urology_sub
Genitourinary Disorders
http://pedsinreview.aappublications.org/cgi/collection/genitourinary_disorders_sub

Permissions & Licensing

Information about reproducing this article in parts (figures, tables) or in its entirety can be found online at:
</site/misc/Permissions.xhtml>

Reprints

Information about ordering reprints can be found online:
</site/misc/reprints.xhtml>

American Academy of Pediatrics

DEDICATED TO THE HEALTH OF ALL CHILDREN™

